




Available online at  
**ScienceDirect**  
[www.sciencedirect.com](http://www.sciencedirect.com)

Elsevier Masson France  
**EM|consulte**  
[www.em-consulte.com/en](http://www.em-consulte.com/en)



## Review

# Artificial Intelligence: Applications in orthognathic surgery

P. Bouletreau<sup>a,b,\*</sup>, M. Makaremi<sup>c</sup>, B. Ibrahim<sup>a,b</sup>, A. Louvrier<sup>d</sup>, N. Sigaux<sup>a,b</sup>

<sup>a</sup> Department of Maxillofacial and Facial Plastic Surgery, Lyon Sud Hospital, Hospices Civils de Lyon, 165, chemin du Grand Revoyet, 69495 Pierre-Benite cedex, France

<sup>b</sup> Claude-Bernard Lyon 1 University, 43 boulevard du 11 Novembre 1918, 69100 Villeurbanne, France

<sup>c</sup> Département d'Orthopédie dento-faciale, UFR des Sciences Odontologiques, 146, rue Léo-Saignat, 33076 Bordeaux cedex, France

<sup>d</sup> Department of Maxillofacial Surgery and Stomatology, Centre Hospitalier Régional, Universitaire Jean-Minjoz, 3 boulevard Alexandre-Fleming, 25000 Besançon, France

## ARTICLE INFO

### Article history:

Received 20 May 2019

Accepted 11 June 2019

### Keywords:

Artificial Intelligence  
Deep learning  
Orthognathic surgery  
Orthodontics

## ABSTRACT

Artificial Intelligence (AI) applications have already invaded our everyday life, and the last 10 years have seen the emergence of very promising applications in the field of medicine. However, the literature dealing with the potential applications of IA in Orthognathic Surgery is remarkably poor to date. Yet, it is very likely that due to its amazing power in image recognition AI will find tremendous applications in dento-facial deformities recognition in a near future. In this article, we point out the state-of-the-art AI applications in medicine and its potential applications in the field of orthognathic surgery. AI is a very powerful tool and it is the responsibility of the entire medical profession to achieve a positive symbiosis between clinical sense and AI.

© 2019 Elsevier Masson SAS. All rights reserved.

## 1. Introduction

Artificial Intelligence (AI) is commonly defined as “a system’s ability to correctly interpret external data, to learn from such data, and to use those learnings to achieve specific goals and tasks through flexible adaptation” [1]. The dramatic increase in computer power over the past 50 years linked to the big data invasion pushed AI applications towards new frontiers. AI is already ubiquitous in our everyday life through our smartphones and cars. It has now gone on to invade the field of medicine. The last five years have shed some light on very promising applications of AI in radiology, dermatology and oncology. Herein, we present the present and potential future applications of AI in the field of orthognathic surgery.

## 2. History

Based on Alan Turing’s research work on machine intelligence, the field of AI research officially emerged in the stream of the so-called “Dartmouth Conference” in 1956. After 20 years of initial

excitement, the technical limitations of AI programming led to its “first winter”: a period marked by massive disinterest of financial investors in this field. In the United Kingdom, the 1973 “Lighthill report” severely criticized the failure of AI projects to achieve their planned goals. In the United States (US), the Mansfield Amendments published in 1969 and 1973 demanded that research funded by the Department of Defense should have direct applications in the US army. AI was considered a technique without any scientific or economic potential and hence lost its funding from the Defense budget for almost 6 years.

At the beginning of the 80s, a new form of AI emerged called “expert systems”. This AI was highly promoted by the Japanese government. In that decade, AI research benefited from a new boost as funding worldwide increased once again. This period was marked by some key developments for training neural networks such as back propagation. However, the market grew progressively disillusioned as this technology did not yield any major economic breakthrough. By the end of the 80s, investor funding once again collapsed leading to the “second winter” of AI. However, research in the field of AI remained active.

In the mid 90s AI finally reached some of its oldest goals. One of its most emblematic milestone was the IBM DeepBlue project which led to the defeat of the world chess champion Gary Kasparov in 1997. This was in part due to increasing computing power.

In the first decade of the XXIst century, AI applications spread rapidly in various fields such as speech recognition, autonomous driving, and medical applications. More recently, the continuous

\* Corresponding author. Department of Maxillofacial and Facial Plastic Surgery, Centre Hospitalier Lyon Sud, 165, chemin du Grand Revoyet, 69495 Pierre-Bénite, France.

E-mail addresses: [pierre.bouletreau@chu-lyon.fr](mailto:pierre.bouletreau@chu-lyon.fr) (P. Bouletreau), [orthodontie@makaremi.fr](mailto:orthodontie@makaremi.fr) (M. Makaremi), [ibra.badr@gmail.com](mailto:ibra.badr@gmail.com) (B. Ibrahim), [au.louvrier@gmail.com](mailto:au.louvrier@gmail.com) (A. Louvrier), [nicolas.sigaux@chu-lyon.fr](mailto:nicolas.sigaux@chu-lyon.fr) (N. Sigaux).

<https://doi.org/10.1016/j.jormas.2019.06.001>

2468-7855/© 2019 Elsevier Masson SAS. All rights reserved.

increase in computing power coupled to the availability of very large databases (Big data) fueled AI applications to unprecedented levels. Machine learning techniques that had been developed decades ago, such as convolutional neural networks, finally found applications in a wide variety of domains. A notable milestone for deep learning applications was the Google-Alphago project that allowed an AI-powered machine to beat the world Go champion in 2017. Nowadays, AI research involves various fields of expertise such as mathematics, computer sciences, and cognitive science amongst others.

### 3. Applications in medicine

In the past decade, numerous very promising applications of AI have emerged in Medicine [2]. Convolutional Neural Networks trained with massive labeled datasets proved to be very efficient in image recognition. The main reason explaining the actual superiority of AI over human doctors in select sub-specialties of medicine is that machines can be educated with hundreds of thousands of clinical cases. This exceeds by far the clinical experience of even the best specialists in any field. Meanwhile, healthcare data has become more abundant and more complex for each patient. And, the ideal of personalized medicine requires taking into account massive sets of data for each individual patient.

The fear that machines could potentially replace human doctors in a near future is to be taken seriously as the momentum of change in the field of AI research is unprecedented. As such, predicting this evolution is becoming increasingly difficult. However, most experts assume that humans will have to cooperate with a so-called “weak AI” for at least a few more decades. Hence for the time being, it is reasonable to consider AI as a tool that can definitely assist human doctors in various areas such as diagnostic medicine, clinical decision making, and personalized medicine.

The main actors in AI research have entered the global market of connected health many years ago. GAFAM (Google, Amazon, Facebook, Apple, and Microsoft) and their Chinese counterpart BATX (Baidu, Alibaba, Tencent, and Xiaomi) have already massively invested in the field of connected health [3]. For example, Google’s Verily and Deepmind Health already propose AI-powered applications “supporting doctors and nurses to deliver faster, better care to patients” [4]. The massive datasets obtained from these projects (demographic information and clinical data) help in return educate machine learning algorithms. Ultimately, this makes the programs more and more efficient and accurate. Thanks to the huge amount of data analyzed, it is likely that in a near future, AI-powered clinical studies will be statistically more powerful and accurate than “classic” clinical studies – including double-blind randomized controlled trials.

Nowadays, medical applications of AI include – but are not limited to – radiology [5], dermatology [6], neurology [7], ophthalmology [8], oncology [9], cardiology [10], genetics [11], emergency medicine [12], and drug design [13].

### 4. Applications in orthognathic surgery

To date, and to the best of our knowledge, the literature related to the applications of AI in Orthognathic Surgery is very poor. The only published study related to this topic aimed at applying AI to assess the impact of orthognathic treatment on facial attractiveness and estimated age [14]. Applying a computational algorithm based on a Convolutional Neural Network, Patcas et al. showed that most patients’ appearance and attractiveness improved with orthognathic treatment. These findings are in line with most “classic” clinical studies. This paper represents a proof of concept

that AI must be considered a useful tool in evaluating facial alterations after orthognathic surgery.

Furthermore, the use of AI seems particularly well adapted in the context of orthognathic surgery protocols. The impact it could have in the future is quite consequential.

Several different factors support this rationale:

- colossal investments are being made by the industry in research and development of AI applied to digital orthodontics and robotic surgery. Large economic returns are expected from these fields (an estimated 3,6 billion € in the field of orthodontics alone);
- the worldwide development of substantial image databases is a proof of the increasing use of digital imagery and photographs in the management of orthognathic cases. Specifically, the introduction of intra-oral scanners has radically altered the place of digital imaging in orthodontics and orthognathic surgery;
- real-life demands from practitioners: reconstruction, tridimensional morphometrics, automated treatment planning, customized surgical set up planning, etc.

At the outset, it is important to identify the type of AI that is being discussed in this instance. A high level of AI in medicine is characterized by an autonomous machine that is capable of evaluating different solutions based on a predictable pathologic evolution. This solution is not yet possible in surgical-orthodontic protocols nor in general orthodontics.

A weak level of AI is an artificial intelligence that is “non-discernable” and can only concentrate on one specific task. In orthognathic surgery, digital solutions are introduced strictly for the analysis of digital models of dental arches and radiographic imagery.

The impact of digital solutions on surgical-orthodontic protocols can be grouped in the following 4 domains (Fig. 1):

- improved diagnostic precision using AI enhanced maxillofacial imagery;
- treatment planning using 3D models;
- CAD/CAM (Computer Aid Design, Computer Aid Manufacturing) manufacture of custom orthodontic and surgical appliances and equipment;
- improved therapeutic follow-up due to finer interval comparison of results using image superimposing.

#### 4.1. Maxillofacial imagery

AI intervenes at different levels to optimize the acquisition and processing of data, as well as pre-analysis of maxillofacial imagery. The various levels of resolution that can be analyzed offer the practitioner a more transparent and global view of the patient’s physical characteristics. This is input is essential for determining the correct therapeutic option.

##### 4.1.1. Acquisition

The use of AI in intra-oral scanner software allows for a quicker and more efficient acquisition. Moreover, the use of AI in tridimensional radiology optimizes the signal to noise ratio and yields higher quality images using lower doses of radiation [15].

##### 4.1.2. Interpretation

The techniques employed in machine learning allow for 3D reconstructions that are rapidly increasing in efficiency. They allow for superimposing of various diagnostic tools (i.e. CBCT, digital photography, and intra-oral scanners) [16] to identify and

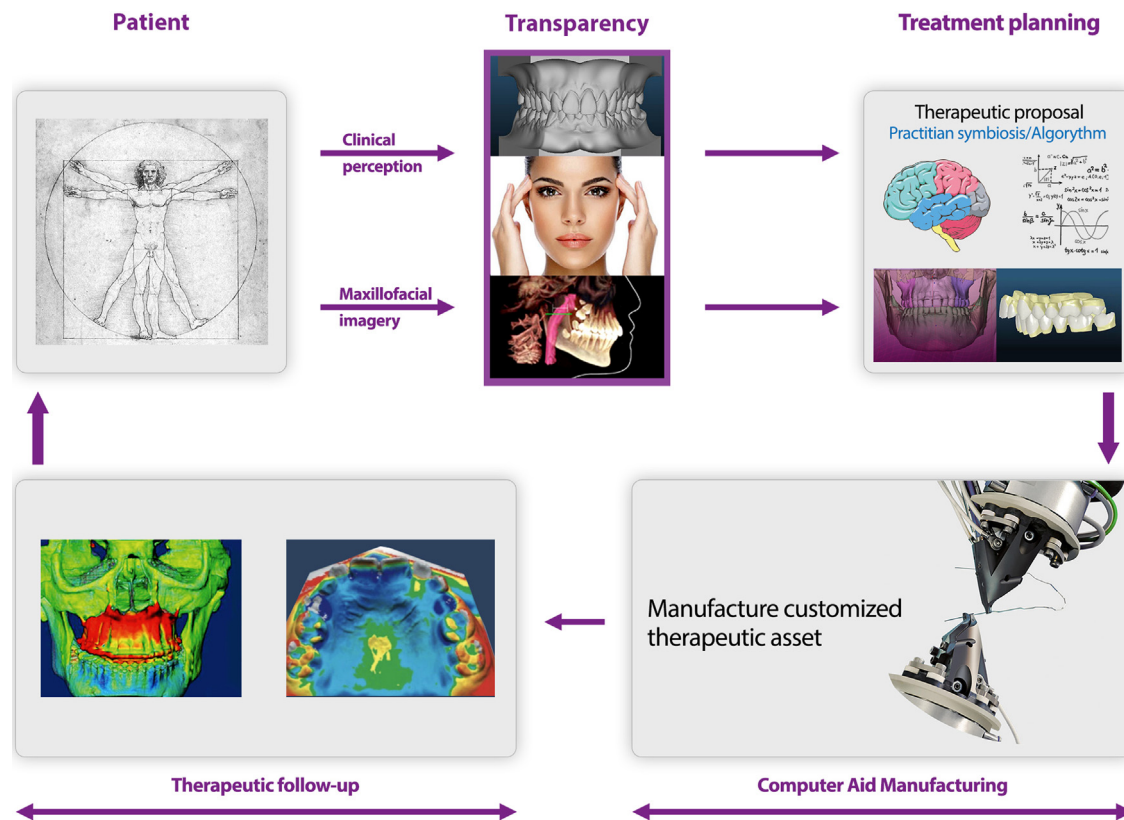


Fig. 1. Digital workflow on surgical-orthodontic protocols.

calculate the dimensions of the upper airways. This data is particularly pertinent in the treatment of obstructive sleep apnea syndromes [17].

Moreover, the analysis of a lateral cephalogram is quite unrewarding for practitioners. However, it is essential in an orthodontic surgery protocol. Various software exist that incorporate artificial intelligence and machine learning [18] technologies to automate cephalometric analyses (Fig. 2). This frees up cognitive resources for the practitioner. Moreover, AI's benefit extends well beyond its 2D analyses capacity. In fact, it enables the practitioner to achieve a true and objective tridimensional perception of a given patient's dento-facial characteristics. It could therefore be a dramatically powerful diagnostic tool. Studies show that a minimum of 100–200 craniometric points are necessary for a biometric analysis of a 3D Cone Beam image of the face [19]. The need for artificial intelligence lies in its capacity to succinctly analyze and interpret so many parameters at once [20].

Currently, ambitious AI solutions are being developed with the aim of producing a literary synthesis from biometric data. For example, an AI would diagnose a “right hemifacial excess” when there is a simultaneous right antero-posterior excess, a right vertical excess, associated with a left mandibular deviation.

#### 4.2. Treatment planning

The surgical-orthodontic planning presents several different challenges. It is the result of the symbiosis between the surgeon and the orthodontist and cannot be purely instinctive. It must be carefully discussed and verbalized in an ongoing dialogue within the team:

- the planning must take into account the orthodontic phase, which is a long-term process, as opposed to the short-term process of surgery;

- the planning should also take into account the numerous interdependent variables: bony structures, occlusion, periodontal health, orofacial functions (swallowing, breathing, etc.), and facial aesthetics. It is worth noting that while some of these parameters can be quantified others need a more subjective evaluation.

These paradigms show the need for 3D digital treatment planning software. This can be achieved using a dynamic virtual set up (Clin Check, Insignia, Orthoanalysier, etc.). These software are enhanced by machine learning [21]. Algorithms have replaced the long and fastidious task of setting up plaster stone models and lateral cephalograms.

The dynamic virtual set up are a wonderful dialogue tool between the maxillofacial surgeon and the orthodontist. It allows the practitioners to visualize diagrams of each therapeutic objective and the role of each intervention on the overall result. It is also a very effective tool for dialogue and planning where there is a multidisciplinary approach involved in the orthognathic surgery protocols (ENT, general dentist, sleep specialist) as these specialists may not be as familiar with the technicalities of orthodontic surgery protocols. Virtual set up software are also great tools to discuss and explain the procedures to the patient in order to improve their understanding and implication in the orthognathic-surgical protocol [22].

#### 4.3. Custom orthodontic and surgical appliances

Following the planning phase, the next step using the CAD/CAM technology allows the custom manufacturing of medical devices. Indeed, 3D printing contributed to the digital revolution that has allowed innovative and invisible treatments (clear aligner treatments, or lingual therapy) [23]. It also allows for creating appliances that incorporate the biomechanics of alveolar decompression (Fig. 3).



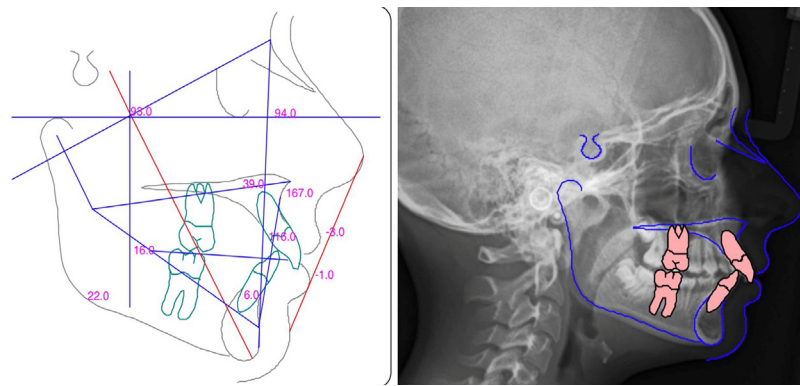


Fig. 2. CephX uses artificial intelligence and machine learning technologies to automate cephalometric analysis<sup>19</sup>.

In the field of orthognathic surgery, CAD/CAM technology found recent applications in treatment planning and transfer methods.

Standard surgical planning may be achieved by cephalometric and clinical planning. In addition, Virtual Surgical Planning (VSP) has been developed as an extension to these standard methods and is now accepted as a very powerful tool to assist the surgeon in most difficult cases such as facial asymmetries [24]. Moreover, the dematerialized medical data it generates makes remote collaboration between practitioners more fluid.

As far as transfer (i.e. clinical application of the planning) is concerned, CAD/CAM technology brought about significant progress in the last decade. Currently available transfer technologies include CAD/CAM surgical splints, CAD/CAM splints with

extra-oral bone support, patient-specific osteosynthesis titanium miniplates, and surgical navigation [25] (Fig. 4).

#### 4.4. Treatment follow-up

Visualizing and quantifying the impact of a given treatment on different anatomical structures presents several advantages in orthognathic surgery. It allows the practitioner to validate the chosen optimal treatment plan and evaluate the pros and cons of alternative treatment options. Additionally, it offers the opportunity for patients to visualize the effects of the treatment hence optimizing informed consent. In addition, it enhances the work of the orthodontist and maxillofacial surgeon by objectively

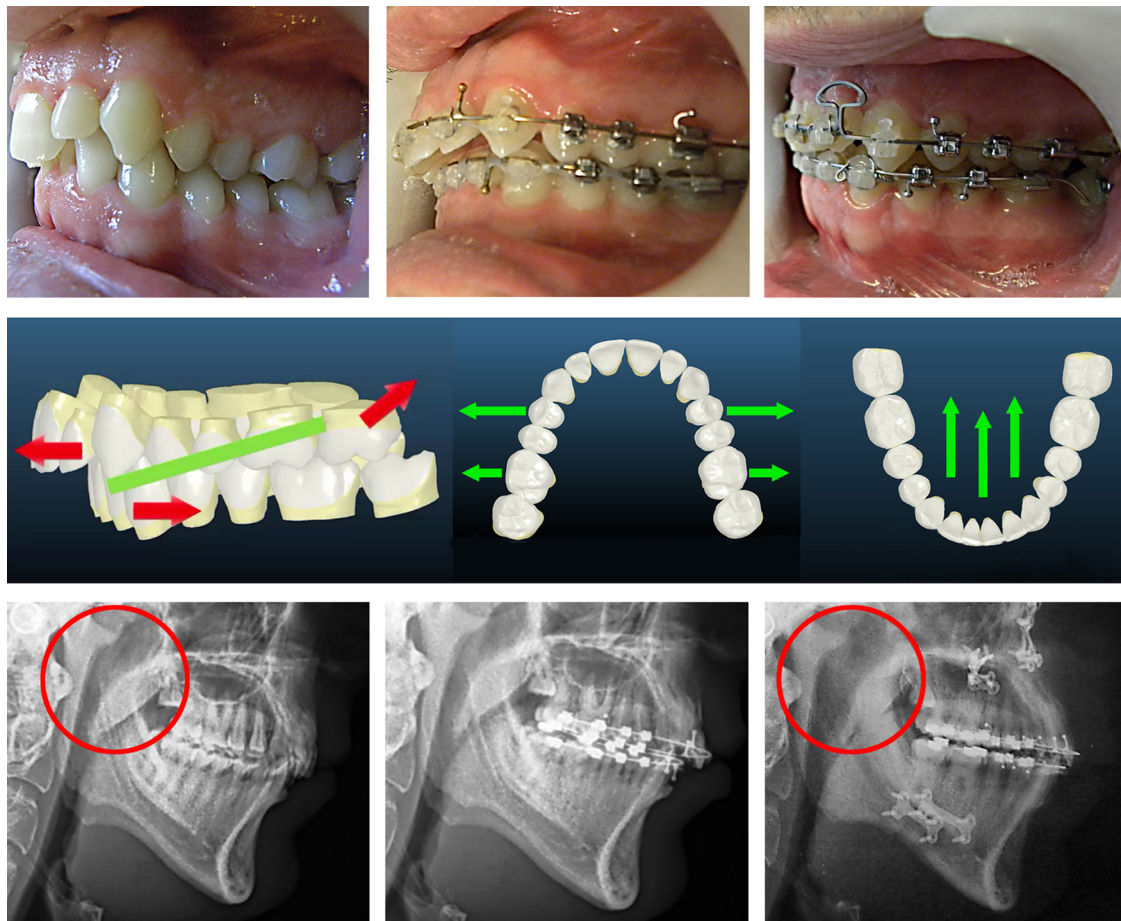
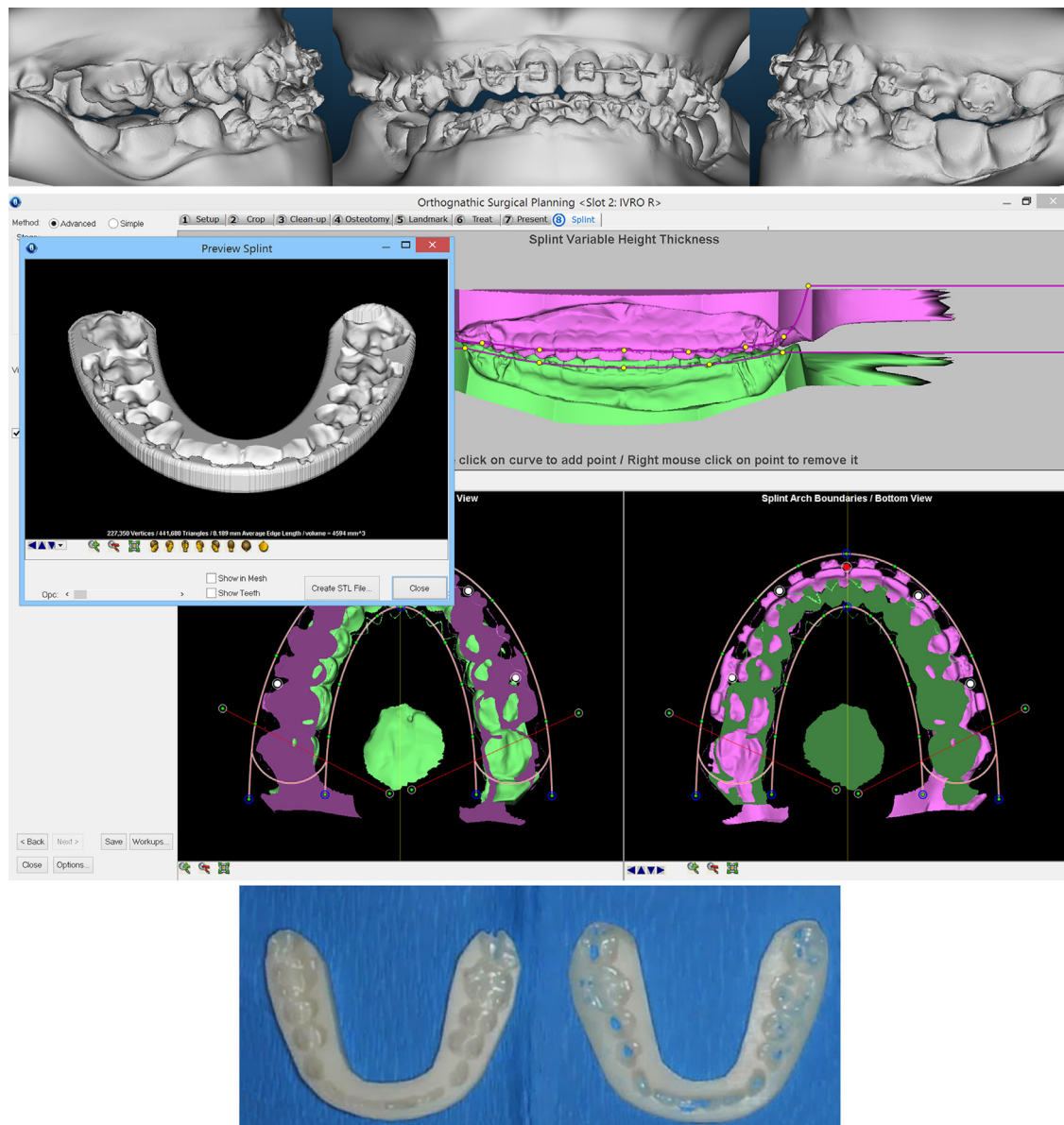


Fig. 3. With CAD/CAM technology the biomechanics of alveolar decompensation could be incorporate on the appliance Insignia (Ormco).



**Fig. 4.** Realization of digital casts (Ormco), virtual construction of the surgical splint (Dolphin imaging), 3D printing of surgical splints (AAO).

presenting the impact of the different phases of the treatment through a non-biased filter. Moreover, the use of AI would allow the practitioner to be better equipped to tackle future clinical challenges with similar presentations.

AI is particularly well adapted as a tool for treatment follow-up as it allows for the superposition of various digital images.

For example, software that was designed with different types of machine learning available for use in the same intra-oral scanner [26,27] allows for the superimposition and visualization of dental arch movements of two digital models in a single patient side-by-side [26,27] (Fig. 5).

Other AI based solutions offer the ability to combine digital photography and 3 D models called “3D Matching” to yield a 3D image of the dental arch models using the actual teeth photographs. This model is dynamically adjusted based on the evolution of the treatment over time [28] (Fig. 6).

Naturally, in orthognathic surgery, the ability to superimpose X ray imaging is particularly useful [29]. Thanks to the abilities of artificial intelligence in 3D radiology, it is possible to automate the use of geometric morphometric tools such as Procuste methods

without a burdensome and labor intensive intervention from a practitioner. The generated images can be Procuste superimpositions entirely [30], or limited to a designated area that is considered stable [31]. Notably in mandibular advancement surgery, a superimposition of a “designated area” comprised of the sagittal ramus posterior to the osteotomy is of great importance.

## 5. Discussion

The extraordinarily fast pace of progresses in the field of computer technology during the last 20 years, following Moore's law, makes it very difficult to predict the path that AI intrusion in the medical field will follow in the future. However, as far as the current applications of AI in medicine are concerned, it seems reasonable to hypothesize that physicians and AI will closely cooperate in a near future. Regarding orthognathic surgery specifically, it is worth contemplating how AI could enhance human capacities in elaborating a treatment plan and what its limitations are in this specific task.



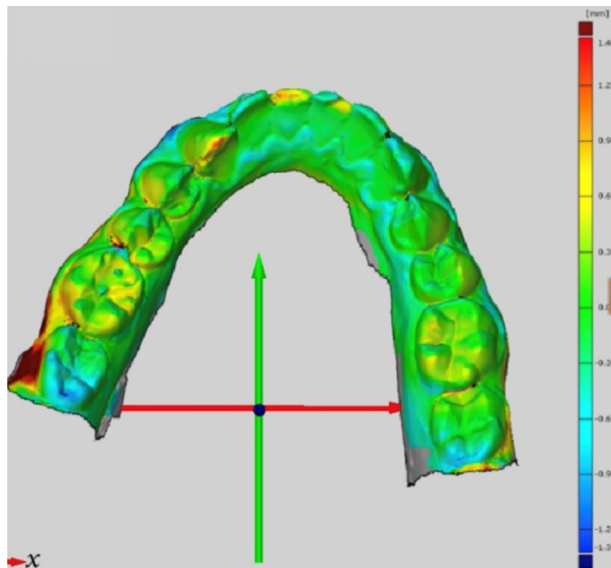


Fig. 5. Superimposition of 3D digital models (3 shape software).

Elaborating a treatment plan in orthognathic surgery is based on three main components. The first component is a basic knowledge in the fields of craniofacial anatomy, orofacial functions, dysmorphisms and their etiologies, as well as surgical techniques. This component is acquired through textbook knowledge and personal experience.

The second component is linked to the artistic sense of each physician. Indeed, facial aesthetics is a major feature of orthognathic surgery, and elaborating a treatment plan requires a certain artistic sensitivity on the surgeon's behalf. The latter must be able to perform an accurate facial esthetic examination. Furthermore, the surgeon must be able to predict the esthetic impact of the skeletal displacements of the maxilla and mandible necessary to correct the dental malocclusion. To this effect, Dr. Harvey Rosen's principles deserve to be considered with great interest: "Soft-tissue goals must influence the direction and extent of skeletal displacements" [32]. This component is mainly acquired through personal experience gained from contact with patients and an artistic sense. The latter is forged away from the operating theaters. It is developed while contemplating arts, discovering museums, observing nature and overall increasing one's general culture about mankind and its societies.

The third component is the patient's demand for a treatment. The orthodontist-surgeon team must carefully assess the actual reason(s) that make the patient seek an orthodontic-surgical protocol. It must be emphasized that even if most patients bring forward functional complaints during the first consultation (i.e. speech problems, masticatory disorders, TMJ dysfunctions, periodontal

health issues etc), the core reason usually motivating patients for these procedures is an improvement of their facial aesthetics [33]. In other words, being a well-trained artistically-educated physician is just not enough if you don't meet the actual patient's demand.

As far as the first component (Basic Knowledge) is concerned, there is little doubt that machines have by far exceed human capacities in storing and organizing data. Today, no human physician can compete with a computer as far as memorization of data is concerned. That's why the IBM-Watson system beat the best human players at Jeopardy – a general knowledge game – back in 2011. And, the amount of data for each patient has grown to a point where we are unable to comprehend it all in its entirety. However, while Silicon brains easily beat their biological counterparts in terms of pure theoretical knowledge, they lag far behind in the field of autonomous technical and procedural expertise. Indeed, robotics in surgery have primarily developed in the field of minimally-invasive surgery but it remains a very costly process [34]. Thus its development has been hindered.

The second component is linked to the artistic sense of the surgeon. Here again we are faced with a balance of advantages and limitations of AI over the human brain that is interesting to consider. Establishing a diagnosis requires a formal static and dynamic facial aesthetic examination. Deep learning techniques based on neural networks (and more specifically convolutional neural networks) proved very efficient at image recognition as proven by Patcas et al.'s demonstration of AI's ability to assess the impact of orthognathic treatment on facial attractiveness and estimated age [14]. Thus, it can be hypothesized that in a near future deep learning algorithms educated with hundreds of thousands of expert-labelled clinical cases will be at least equivalent to the best maxillofacial surgeons at establishing the diagnosis of a dento-facial dysmorphism. Computer-aided facial recognition tools are already routinely used to help doctors diagnose rare craniofacial genetic disorders [35].

However, AI has yet to demonstrate its value and capacities in the field of simulation of outcomes of orthognathic surgery. Indeed, the question of the virtual simulation of the postoperative aesthetic result remains unanswered to date. Skeletal displacements induce soft-tissue alterations that are very difficult to predict, especially in the nasolabial region, as the skin, subcutaneous adipose tissues, muscles and mucosa have distinct Young's modulus. The soft-tissue response to the underlying skeletal displacements can be quite different according to the quality of the soft-tissues linked to various factors such as (age, sex, ethnics, body max index, etc.) and vary from one patient to the other. Therefore, it seems still very unlikely that an algorithm could accurately predict the planned final aesthetic result after an orthognathic surgery in a near future. Although this information is of key importance to most (if not all) patients, modern maxillofacial surgeons address this subject with their patients with great care on the basis of their own experience and clinical examination.

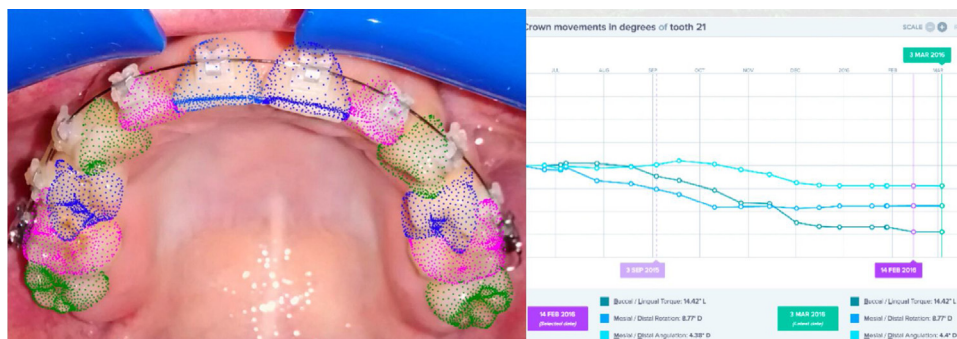


Fig. 6. 3 D Matching by dental monitoring.

Not the least to consider is the third component in the elaboration of a treatment plan. Patient satisfaction is the ultimate goal the orthodontist-maxillofacial surgeon team should aim for. This satisfaction is linked to the appreciation by the patient that the treatment achieved the planned objectives. As stated above, accurately assessing the core motivation(s) of a patient seeking an orthodontic-surgical treatment requires a very fine analysis from the physician. Patients' demands are often ambiguous in the field of craniofacial dysmorphisms and it needs all the experience of a well-trained physician to detect patient's real motivation(s) and elaborate a personalized treatment plan. Beyond the natural empathy that should be part of the doctor-patient relationship, the orthodontist and maxillofacial surgeon should really try to "comprehend" (etymologically "to take with oneself") the patient's symptoms and demands. And, likewise the agreed upon treatment plan should be "comprehensible" by the patient so that he can really be involved in it. We believe this third component is definitely the one that demands the more human skills, as machines are not at ease when dealing with ambiguous data.

On the other hand, an overdependence to the enhanced capacities that AI offers in every step of the process of an orthodontic surgery protocol carries an obvious inherent risk: loss of intrinsic specialist skills. By allowing the practitioner to rely too heavily on computerized algorithms and simply execute established treatment plans, practitioners could lose their clinical and technical sense of reasoning in the long-term [36]. The lack of use of specific skills learned and acquired by clinical experience could suffer if critical thinking is not used in conjunction with these new methods [37].

## 6. Conclusion

The number of digital tools available based on artificial intelligence will have an immense impact on orthognathic-surgical treatment plans from the initial diagnosis to follow-up treatment. This paradigm change brings with it several obvious beneficial effects:

- the passage from 2D to 3D imagery along with added benefits of increased diagnostic precision;
- the possibility to visualize the treatment plan and engage patients and practitioners in a constructive dialogue. This limits confusion and brings a unique treatment plan for each patient using the CAD/CAM technology;
- the assistance and collaboration of a software capable of assisting practitioners in all steps from treatment planning to treatment follow-up. Such a software would have the ability to learn from every real-life case it is exposed to improve its performance on the following cases.

Therefore, it is the responsibility of the entire medical profession to successfully manage the use of artificial intelligence in the diagnosis and treatment of patients and to achieve a positive symbiosis between clinical sense and AI. In order to achieve this, artificial intelligence needs to be viewed as a tool to be used with the utmost care and training, and not as a threat.

## Disclosure of interest

The authors declare that they have no competing interest.

## References

- [1] Kaplan A, Haenlein M. Siri, Siri, in my hand: who's the fairest in the land? On the interpretations, illustrations, and implications of artificial intelligence. *Bus Horiz* 2019;62(1):15–25. <http://dx.doi.org/10.1016/j.bushor.2018.08.004>.
- [2] Jiang F, Jiang Y, Zhi H, et al. Artificial intelligence in healthcare: past, present and future. *Stroke Vasc Neurol* 2017;2(4):230–43. <http://dx.doi.org/10.1136/svn-2017-000101>.
- [3] Lee K-F. *AI Superpowers: China, Silicon Valley and the New World Order*. Boston: Mass: Houghton Mifflin; 2018.
- [4] <https://deepmind.com/applied/deepmind-health/>.
- [5] Saba L, Biswas M, Kuppli V, et al. The present and future of deep learning in radiology. *Eur J Radiol* 2019;114:14–24. <http://dx.doi.org/10.1016/j.ejrad.2019.02.038>.
- [6] Esteve A, Kuprel B, Novoa RA, et al. Dermatologist-level classification of skin cancer with deep neural networks. *Nature* 2017;542(7639):115–8. <http://dx.doi.org/10.1038/nature21056>.
- [7] Lee E-J, Kim Y-H, Kim N, Kang D-W. Deep into the brain: Artificial Intelligence in Stroke Imaging. *J Stroke* 2017;19(3):277–85. <http://dx.doi.org/10.5853/jos.2017.02054>.
- [8] Hogarty DT, Mackey DA, Hewitt AW. Current state and future prospects of artificial intelligence in ophthalmology: a review. *Clin Experiment Ophthalmol* 2019;47(1):128–39. <http://dx.doi.org/10.1111/ceo.13381>.
- [9] Bibault J-E, Burgun A, Giraud P. Intelligence artificielle appliquée à la radiothérapie. *Cancer Radiother* 2017;21(3):239–43. <http://dx.doi.org/10.1016/j.canrad.2016.09.021>.
- [10] Marr B. First FDA approval for clinical cloud-based deep learning in healthcare. [Available from: <https://www.forbes.com/sites/bernardmarr/2017/01/20/first-fda-approval-for-clinical-cloud-based-deep-learning-in-healthcare/#3a4a9bca161c>]
- [11] Otake T. IBM big data used for rapid diagnosis of rare leukemia case in Japan. *The Japan Times*. [Available from: <https://www.japantimes.co.jp/news/2016/08/11/national/science-health/ibm-big-data-used-for-rapid-diagnosis-of-rare-leukemia-case-in-japan/#.XMniRy3pNmA>]
- [12] Ghassemi M, Celi L, Stone DJ. State of the art review: the data revolution in critical care. *Crit Care* 2015;19(1):118. <http://dx.doi.org/10.1186/s13054-015-0801-4>.
- [13] Zhong F, Xing J, Li X, et al. Artificial intelligence in drug design. *Sci China Life Sci* 2018;61(10):1191–204. <http://dx.doi.org/10.1007/s11427-018-9342-2>.
- [14] Patcas R, Bernini DAJ, Volokitin A, Agustsson E, Rothe R, Timofte R. Applying artificial intelligence to assess the impact of orthognathic treatment on facial attractiveness and estimated age. *Int J Oral Maxillofac Surg* 2019;48(1):77–83. <http://dx.doi.org/10.1016/j.ijom.2018.07.010>.
- [15] Sun Y, Liu X, Cong P, Li L, Zhao Z. Digital radiography image denoising using a generative adversarial network. *J Xray Sci Technol* 2018;26(4):523–34. <http://dx.doi.org/10.3233/XST-17356>.
- [16] Cevdanes LHS, Styner MA, Proffit WR. Image analysis and superimposition of 3-dimensional cone-beam computed tomography models. *Am J Orthod Dentofac Orthop* 2006;129(5):611–8. <http://dx.doi.org/10.1016/j.ajodo.2005.12.008>.
- [17] Kamaruddin N, Daud F, Yusof A, Aziz ME, Rajion ZA. Comparison of automatic airway analysis function of InVivo5 Romexis software. *Peer J* 2019;7:e6319. <http://dx.doi.org/10.7717/peerj.6319>.
- [18] Nishimoto S, Sotsuka Y, Kawai K, Ishise H, Kakibuchi M. Personal computer-based cephalometric landmark detection with deep learning using cephalograms on the Internet. *J Craniofac Surg* 2019;30(1):91–5. <http://dx.doi.org/10.1097/SCS.0000000000004901>.
- [19] Zamora N, Llamas J-M, Cibrián R, Gandia J-L, Paredes V. A study on the reproducibility of cephalometric landmarks when undertaking a three-dimensional (3D) cephalometric analysis. *Med Oral Patol Oral Cir Bucal* 2012;17(4):e678–88 [Available from: <http://www.ncbi.nlm.nih.gov/pubmed/22322503>].
- [20] Faure J, Oueiss A, Treil J, Chen S, Wong V, Inglesse JM. 3D cephalometry and artificial intelligence. *J Dentofac Anomalies Orthod* 2016;19(4):409. <http://dx.doi.org/10.1051/odfen/2018117>.
- [21] Hennessy J, Al-Awadhi EA. Clear aligners generations and orthodontic tooth movement. *J Orthod* 2016;43(1):68–76. <http://dx.doi.org/10.1179/1465313315Y.00000000000004>.
- [22] Pagani R, Signorino F, Poli PP, Manzini P, Panisi I. The use of Invisalign® system in the management of the orthodontic treatment before and after class III surgical approach. *Case Rep Dent* 2016;2016:9231219. <http://dx.doi.org/10.1155/2016/9231219>.
- [23] Lagravère MO, Flores-Mir C. The treatment effects of Invisalign orthodontic aligners: a systematic review. *J Am Dent Assoc* 2005;136(12):1724–9 [Available from: <http://www.ncbi.nlm.nih.gov/pubmed/16383056>].
- [24] Steinhuber T, Brunold S, Gärtner C, Offermanns V, Ulmer H, Ploder O. Is virtual surgical planning in orthognathic surgery faster than conventional planning? A time and workflow analysis of an office-based workflow for single- and double-jaw surgery. *J Oral Maxillofac Surg* 2018;76(2):397–407. <http://dx.doi.org/10.1016/j.joms.2017.07.162>.
- [25] Pascal E, Majoufre C, Bondaz M, Courtemanche A, Berger M, Bouletreau P. Current status of surgical planning and transfer methods in orthognathic surgery. *J Stomatol Oral Maxillofac Surg* 2018;119(3):245–8. <http://dx.doi.org/10.1016/j.jormas.2018.02.001>.
- [26] José Viñas M, Pie de Hierro V, Ustrell-Torrent MJ. Superimposition of 3D digital models: a case report. *Int Orthod* 2018;16(2):304–13. <http://dx.doi.org/10.1016/j.ortho.2018.03.017>.
- [27] Ganzer N, Feldmann I, Liv P, Bondemark L. A novel method for superimposition and measurements on maxillary digital 3D models-studies on validity and reliability. *Eur J Orthod* 2018;40(1):45–51. <http://dx.doi.org/10.1093/ejo/cjx029>.

- [28] Roisin L-C, Brézulier D, Sorel O. Contrôle à distance en orthodontie : fondements et description de la solution Dental MonitoringTM. *Rev Orthop Dento Faciale* 2016;50(3):303–13. <http://dx.doi.org/10.1051/odf/2016021>.
- [29] Cevidanes L, Bailey L, Tucker G, et al. Superimposition of 3D cone-beam CT models of orthognathic surgery patients. *Dentomaxillofac Radiol* 2005;34(6):369–75. <http://dx.doi.org/10.1259/dmfr/17102411>.
- [30] Oueiss A. Les rapports tridimensionnels de la base du crâne et du massif maxillo-facial : intérêts en orthodontie et anthropobiologie; 2010 [Available from: <http://www.theses.fr/2010TOU30027>].
- [31] Oueiss A, Pages C, Treil J, Braga J, Baron P, Faure J. Étude des asymétries dans les grandes dysmorphies antéro-postérieures. *Orthod Française* 2010;81(3): 235–244. <http://dx.doi.org/10.1051/orthodfr/2010022>.
- [32] Rosen HM. *Aesthetic perspectives in jaw surgery*; 1999.
- [33] Patcas R, Cunningham SJ, Shute J, et al. Motivation for orthognathic treatment and anticipated satisfaction levels – a two-centre cross-national audit. *J Cranio-Maxillofac Surg* 2017;45(6):1004–9. <http://dx.doi.org/10.1016/j.jcms.2017.03.012>.
- [34] Troccaz J, Dagnino G, Yang G-Z. Frontiers of medical robotics: from concept to systems to clinical translation. *Annu Rev Biomed Eng* 2019;21(1). <http://dx.doi.org/10.1146/annurev-bioeng-060418-052502> [annurev-bioeng-060418-052502].
- [35] Hurst ACE. Facial recognition software in clinical dysmorphology. *Curr Opin Pediatr* 2018;30(6):701–6. <http://dx.doi.org/10.1097/MOP.0000000000000677>.
- [36] Makaremi M. The role of cognitive sciences in orthodontic treatments: optimizing the interface between practitioners and new technologies. *J Dentofac Anomalies Orthod* 2016;19(4):410. <http://dx.doi.org/10.1051/odfen/2018116>.
- [37] Makaremi M. Les enjeux d'une nouvelle interface. *Rev Orthop Dento Faciale* 2018;52(4):319–24. <http://dx.doi.org/10.1051/odf/2018026> [Guiral-Desnoës H, ed.].